

ICES IDENTIFICATION LEAFLETS FOR DISEASES AND PARASITES OF FISH AND SHELLFISH

Leaflet No. 60

Amoebic gill disease (AGD) of farmed Atlantic salmon (*Salmo salar* L.)

Neil M. Ruane and Simon R. M. Jones



ICES

International Council for
the Exploration of the Sea

CIEM

Conseil International pour
l'Exploration de la Mer

International Council for the Exploration of the Sea Conseil International pour l'Exploration de la Mer

H.C. Andersens Boulevard 44–46
DK-1553 Copenhagen V
Denmark
Telephone (+45) 33 38 67 00
Telefax (+45) 33 93 42 15
www.ices.dk
info@ices.dk

Recommended format for purposes of citation:

Ruane, N. M. and Jones, S. R. M. 2013. Amoebic Gill Disease (AGD) of farmed Atlantic salmon (*Salmo salar* L.). ICES Identification Leaflets for Diseases and Parasites of Fish and Shellfish. Leaflet No. 60. 6 pp.

Series Editor: Stephen Feist. Prepared under the auspices of the ICES Working Group on Pathology and Diseases of Marine Organisms.

For permission to reproduce material from this publication, please apply to the General Secretary.

ISBN 978-87-7482-136-6
<https://doi.org/10.17895/ices.pub.5241>
ISSN 0109–2510

© 2013 International Council for the Exploration of the Sea

Amoebic gill disease (AGD) of farmed Atlantic salmon (*Salmo salar* L.)

Neil M. Ruane and Simon R. M. Jones

Susceptible species

Amoebic Gill Disease (AGD) primarily affects salmonids and was first described in marine reared coho salmon (*S. kisutch*) in Washington and California, USA (Kent *et al.*, 1988) and in Atlantic salmon (*Salmo salar*) and rainbow trout (*Oncorhynchus mykiss*) in Tasmania (Munday *et al.*, 1993). However, the disease has also been reported in turbot, *Psetta maxima* and sea bass *Dicentrarchus labrax* (Munday *et al.*, 2001) and has recently been described in ballan wrasse, *Labrus bergylta* (Karlsbakk *et al.*, 2013).

Disease name

Amoebic gill disease (AGD).

Aetiological agent

AGD was initially ascribed to *Neoparamoeba pemaquidensis*, based on morphological (Dyková *et al.*, 2000) and molecular characterization (Wong *et al.*, 2004). The isolation of *N. branchiphila* from AGD-affected fish (Dyková *et al.*, 2005) meant that the disease may have a mixed aetiology. However, issues still remained with the development of a reproducible experimental challenge model using both species (Morrison *et al.*, 2004; Vincent *et al.*, 2007). Using molecular techniques, Young *et al.* (2008a) showed that *N. perurans* was the aetiological agent of AGD which was subsequently confirmed by laboratory trials and fulfilment of Koch's Postulates (Crosbie *et al.*, 2012). More recent molecular and morphological evidence supports inclusion of the aetiological agent of AGD, along with related dactylopodial amoebae, within the genus *Paramoeba*, i.e. *P. perurans* (Feehan *et al.*, 2013).

Geographical distribution

The disease has long been associated with farmed Atlantic salmon in Tasmania (Munday *et al.*, 1993) and has also been reported in farmed Atlantic salmon in Ireland (Palmer *et al.*, 1997), Scotland, Norway (Steinum *et al.*, 2008) and Chile (Bustos *et al.*, 2011). The disease has also been reported in the Mediterranean (Dyková *et al.*, 2000; Munday *et al.*, 2001) and in South Africa (Mouton *et al.*, 2013).

Associated environmental conditions

Clinical disease is most commonly reported at temperatures ranging from 12–20°C and at salinities at or above 35‰ (Mitchell and Rodger, 2011).

Significance

AGD has been the most significant health problem for marine salmon aquaculture in Tasmania for many years. Mortalities are generally low due to the control and treatment of the disease which adds significantly to the production costs. The commonly used treatment is a freshwater bath, often repeated every 4–6 weeks

during summer. Therefore any expansion of the industry is constrained by access to freshwater supplies.

Gross clinical signs

AGD is characterized by multifocal lesions that appear as pale gill tissue, or white mucoid spots and plaques. The main histological feature of the disease is prominent epithelial hyperplasia resulting in a complete lamellar fusion. Large mucous cells are often situated on the surface of the hyperplastic epithelium and between the lamellae, with significant leucocyte infiltration (Mitchell and Rodger, 2011).

Control measures and legislation

The recommended treatment for AGD is a 2–3 h freshwater bath (Clark *et al.*, 2003). Treatment with hydrogen peroxide has also shown to be effective (Adams *et al.*, 2012) and is commonly used in Ireland and Scotland when freshwater is not available. AGD is not reportable to the OIE.

Diagnostic methods

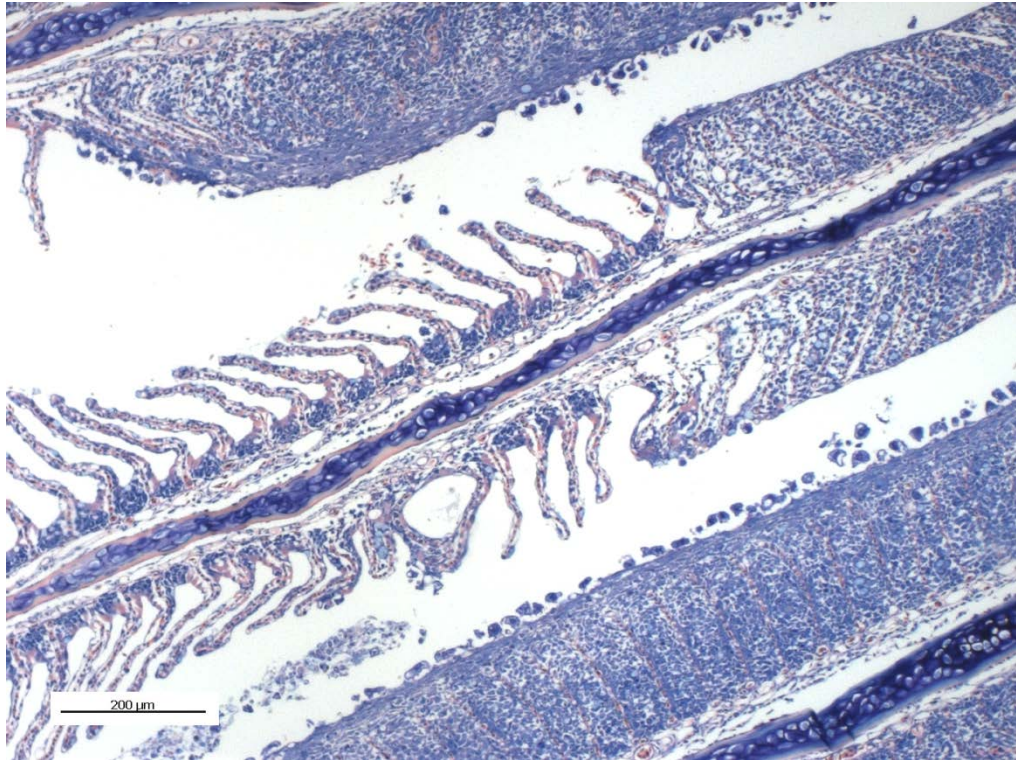
Regular macroscopic examination of gills forms the basis of every control measure for AGD. Commercial farms utilize a field evaluation of 'gross gill score' describing the extent of visible white patches on a scale of 0 (clear) to 5 (heavy) to schedule treatments (Taylor *et al.*, 2009). Macroscopic examination is often supported by gill smears and histopathology to confirm the presence of the parasite. Both conventional PCR (Young *et al.*, 2008b) and real-time TaqMan PCR (Fringuelli *et al.*, 2012) methods have also been described.

Key References

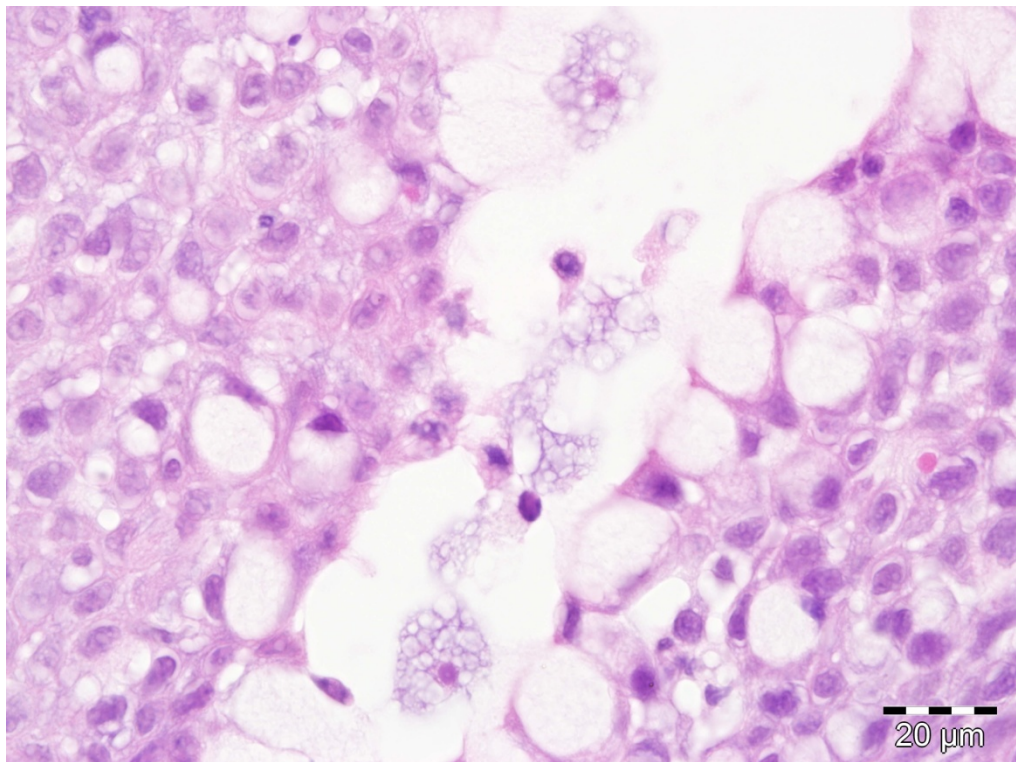
- Adams, M. B., Crosbie, P. B. B., Nowak, B. F. 2012. Preliminary success using hydrogen peroxide to treat Atlantic salmon, *Salmo salar* L., affected with experimentally induced amoebic gill disease (AGD). *Journal of Fish Diseases*, 35: 839–848.
- Bustos, P. A., Young, N. D., Rozas, M. A., Bohle, H. M., Ildefonso, R. S., Morrison, R. N., Nowak, B. F. 2011. Amoebic gill disease (AGD) in Atlantic salmon (*Salmo salar*) farmed in Chile. *Aquaculture*, 310: 281–288.
- Clark, G., Powell, M., Nowak, B. 2003. Effects of commercial freshwater bathing on reinfection of Atlantic salmon, *Salmo salar*, with Amoebic Gill Disease. *Aquaculture*, 219: 135–142.
- Crosbie, P. B. B., Bridle, A. R., Cadoret, K., Nowak, B. F. 2012. *In vitro* cultured *Neoparamoeba perurans* causes amoebic gill disease in Atlantic salmon and fulfils Koch's postulates. *International Journal for Parasitology*, 42: 511–515.
- Dyková, I., Figueras, A., Peric, Z. 2000. *Neoparamoeba* Page, 1987: light and electron microscopic observations on six strains of different origin. *Diseases of Aquatic Organisms*, 43: 217–223.
- Dyková, I., Nowak, B. F., Crosbie, P. B. B., Fiala, I., Pecková, H., Adams, M. B., Macháčková, B., Dvořáková, H. 2005. *Neoparamoeba branchiphila* n. sp., and related species of the genus *Neoparamoeba* Page, 1987: morphological and molecular characterization of selected strains. *Journal of Fish Diseases*, 28: 49–64.
- Feehan, C. J., Johnson-Mackinnon, J., Scheilbling, R. E., Lauzon-Guay, J.-S., Simpson, A. G. B. 2013. Validating the identity of *Paramoeba invadens*, the causative agent of

- recurrent mass mortality of sea urchins in Nova Scotia, Canada. *Diseases of Aquatic Organisms*, 103: 209–227.
- Fringuelli, E., Gordon, A. W., Rodger, H., Welsh, M. D., Graham, D. A. 2012. Detection of *Neoparamoeba perurans* by duplex quantitative Taqman real-time PCR in formalin-fixed, paraffin-embedded Atlantic salmonid gill tissues. *Journal of Fish Diseases*, 35: 711–724.
- Karlsbakk, E., Olsen, A. B., Einen, A. C. B., Mo, T. A., Fiksdal, I. U., Aase, H., Kalgraff, C., Skår, S. Å., Hansen, H. 2013. Amoebic gill disease due to *Paramoeba perurans* in ballan wrasse (*Labrus bergylta*). *Aquaculture*, doi: 10.1016/j.aquaculture.2013.07.007
- Kent, M. L., Sawyer, T. K., Hedrick, R.P. 1988. *Paramoeba pemaquidensis* (Sarcocystidophora: Paramoebidae) infestation of the gill of coho salmon *Oncorhynchus kisutch* reared in sea water. *Diseases of Aquatic Organisms*, 5: 163–169.
- Mitchell, S. O., and Rodger, H. D. 2011. A review of infectious gill disease in marine salmonid fish. *Journal of Fish Diseases*, 34: 411–432.
- Morrison, R. N., Crosbie, P. B. B., Nowak, B. F. 2004. The induction of laboratory-based amoebic gill disease revisited. *Journal of Fish Diseases*, 27: 445–449.
- Mouton, A., Crosbie, P., Cadoret, K., Nowak, B. 2013. First record of amoebic gill disease caused by *Neoparamoeba perurans* in South Africa. *Journal of Fish Diseases*, doi:10.1111/jfd.12133.
- Munday, B. L., Lange, K., Foster, C., Lester, R., Handler, J. 1993. Amoebic gill disease in sea-caged salmonids in Tasmanian waters. *Tasmanian Fisheries Research*, 28: 14–19.
- Munday, B. L., Zilberg, D., Findlay, V. 2001. Gill disease of marine fish caused by infection with *Neoparamoeba pemaquidensis*. *Journal of Fish Diseases*, 24: 497–507.
- Palmer, R., Carson, J., Ruttledge, M., Drinan, E., Wagner, T. 1997. Gill disease associated with *Paramoeba*, in sea reared Atlantic salmon in Ireland. *Bulletin of the European Association of Fish Pathologists*, 17: 112–114.
- Steinum, T., Kvellestad, A., Rønneberg, L.B., Nilsen, H., Asheim, A., Fjell, K., Nygård, S. M. R., Olsen, A. B., Dale, O. B. 2008. First cases of amoebic gill disease (AGD) in Norwegian seawater farmed Atlantic salmon, *Salmo salar* L., and phylogeny of the causative amoeba using 18S cDNA sequences. *Journal of Fish Diseases*, 31: 205–214.
- Taylor, R. S., Muller, W. J., Cook, M. T., Kube, P. D., Elliott, N. G. 2009. Gill observations in Atlantic salmon (*Salmo salar* L.) during repeated amoebic gill disease (AGD) field exposure and survival challenge. *Aquaculture*, 290: 1–8.
- Vincent, B. N., Adams, M. B., Crosbie, P. B. B., Nowak, B. F., Morrison, R. N. 2007. Atlantic salmon (*Salmo salar* L.) exposed to cultured gill-derived *Neoparamoeba branchiphila* fail to develop amoebic gill disease (AGD). *Bulletin of the European Association of Fish Pathologists*, 27: 112–115.
- Wong, F. Y. K., Carson, J., Elliott, N. G. 2004. 18S ribosomal DNA-based PCR identification of *Neoparamoeba pemaquidensis*, the agent of amoebic gill disease in sea-farmed salmonids. *Diseases of Aquatic Organisms*, 60: 65–76.
- Young, N. D., Dyková, I., Snekvik, K., Nowak, B. F., Morrison, R. N. 2008a. *Neoparamoeba perurans* is a cosmopolitan aetiological agent of amoebic gill disease. *Diseases of Aquatic Organisms*, 78: 217–223.

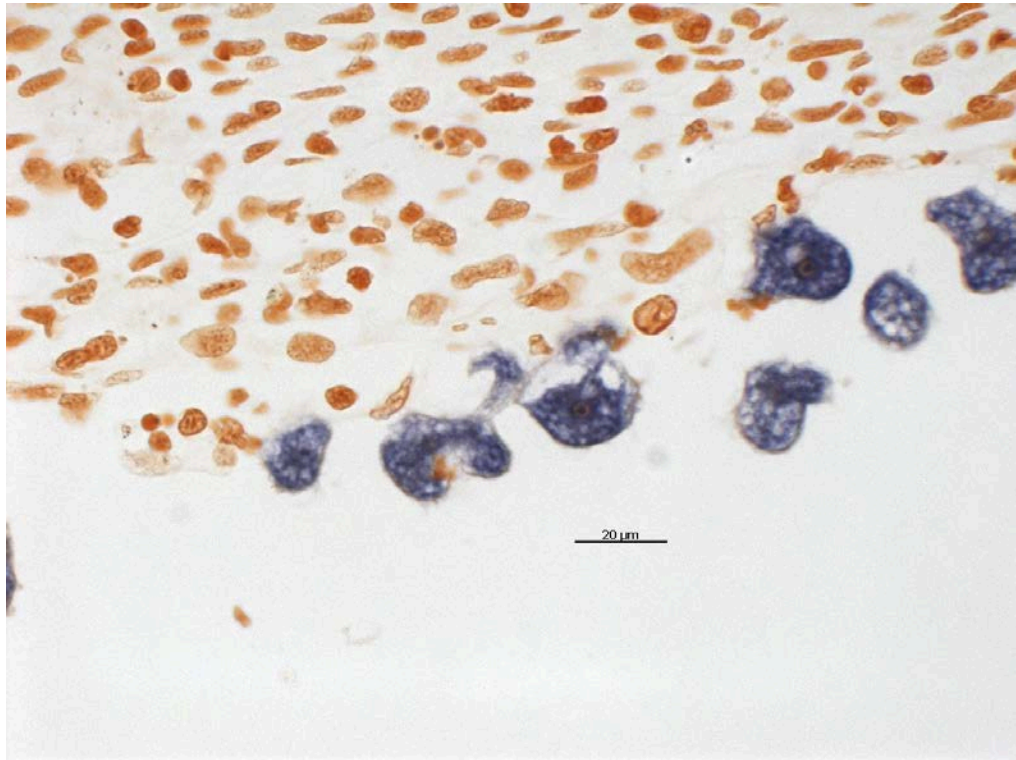
Young, N. D., Dyková, I., Nowak, B. F., Morrison, R. N. 2008b. Development of a diagnostic PCR to detect *Neoparamoeba perurans*, agent of amoebic gill disease. *Journal of Fish Diseases*, 31: 285–295.



Histological section of Giemsa stained gill tissue from AGD affected Atlantic salmon showing hyperplastic lesions and associated amoeba. (Photo: Simon Jones, Fisheries and Oceans Canada).



Histological section of H&E stained gill tissue from Atlantic salmon with AGD showing amoeba and epithelial hyperplasia with abundant mucous cells. (Photo: Evelyn Collins, Marine Institute, Ireland).



Histological section of Atlantic salmon gill with AGD showing *Paramoeba perurans* stained by *in-situ* hybridization. (Photo: Simon Jones, Fisheries and Oceans Canada).

Author Contact Information

Neil Ruane
Marine Institute
Rinville
Oranmore
County Galway
Ireland
neil.ruane@marine.ie

Simon R.M. Jones
Fisheries & Oceans Canada
3190 Hammond Bay Road
Nanaimo
British Columbia V9T 6N7
Canada
simon.jones@dfo-mpo.gc.ca