

ICES IDENTIFICATION LEAFLETS FOR DISEASES AND PARASITES OF FISH AND SHELLFISH

Leaflet No. 30

Dermo disease of oysters caused by *Perkinsus marinus*

Original by Fred Kern

Revised and updated by Susan E. Ford



ICES

International Council for
the Exploration of the Sea

CIEM

Conseil International pour
l'Exploration de la Mer

International Council for the Exploration of the Sea Conseil International pour l'Exploration de la Mer

H.C. Andersens Boulevard 44–46
DK-1553 Copenhagen V
Denmark
Telephone (+45) 33 38 67 00
Telefax (+45) 33 93 42 15
www.ices.dk
info@ices.dk

Recommended format for purposes of citation:

ICES. 2011. Dermo disease of oysters caused by *Perkinsus marinus*. Revised and updated by Susan E. Ford. ICES Identification Leaflets for Diseases and Parasites of Fish and Shellfish. Leaflet No. 30. 5 pp.

Series Editor: Stephen Feist. Prepared under the auspices of the ICES Working Group on Pathology and Diseases of Marine Organisms.

For permission to reproduce material from this publication, please apply to the General Secretary.

<https://doi.org/10.17895/ices.pub.5202>

ISBN 978-87-7482-098-7

ISSN 0109–2510

© 2011 International Council for the Exploration of the Sea

Derma disease of oysters caused by *Perkinsus marinus*

Original by Fred Kern. Revised and updated by Susan E. Ford.

Susceptible species

Primarily the eastern oyster, *Crassostrea virginica* (Gmelin), although it has been reported in the mangrove oyster *C. rhizophorae*, the pleasure oyster *C. corteziensis*, and the Pacific oyster, *C. gigas*.

Disease name

Derma Disease

Aetiological agent

Perkinsus marinus (= *Labyrinthomyxa marina* = *Dermocystidium marinum*), currently classified as a member of the Phylum Apicomplexa; however, genetic sequencing places it closer to the dinoflagellates. Transmission is direct and the parasite can be culture *in vitro*.

Geographical distribution

Infected eastern oysters are found along the east coast of the USA from Maine to Florida; and along the Gulf coast of the United States, Mexico, and Venezuela. *P. marinus* has been identified on the Pacific coast of Mexico in the pleasure oyster and the Pacific oyster. Parasites thought to be *P. marinus* have been found in oysters from Jamaica, Puerto Rico, Cuba, Brazil, and Hawaii although significant mortalities have been reported only in Hawaii. Because the assay used exclusively for some of these identifications (Ray's Fluid Thioglycollate) is not specific, some of the reported findings of *Perkinsus marinus* in molluscs other than eastern oysters may involve other *Perkinsus* species.

Associated environmental conditions

Prevalence has a pronounced seasonal cycle in the eastern oyster. Infections are acquired during the warm months of the year. Parasites proliferate *in vivo* most rapidly at water temperatures above 18°C and salinities greater than 15; however, experimental infections have been achieved at 10°C and 3. Mortalities usually begin as temperatures exceed 20°C and accelerate as they approach 25°C. Infection intensities decline over the winter and spring, most noticeably in northern areas, when the parasite may be difficult to detect using standard methods; however, it is likely that all oysters remain infected and that infections will intensify again with the onset of higher temperatures.

Significance

Perkinsus marinus causes reduction in growth and meat condition followed by mortality of susceptible infected oysters, although most deleterious effects do not occur until the second year of exposure. Mortalities may range from 5 to 30% during the first year of an epizootic, and total from 60 to 80% by the end of the second year. Chronic mortalities averaging 20 to 30% are common in enzootic waters. Disease epizootics were once largely restricted to a region from the lower Chesapeake Bay south along the Atlantic and Gulf coasts of the USA. Beginning in the mid to late 1980s, and coincident with a pronounced winter warming trend, disease outbreaks were reported as far north as southern Maine. The range extension resulted in severe and repeated oyster mortalities in the mid-Atlantic and New England, USA.

Light infections have little measurable impact on the host, but at an advanced stage they reduce feeding, growth and reproduction, leaving oysters weak and emaciated. Unicellular “meront or trophont” stages are often found inside haemocytes, where they survive, proliferate, and are distributed throughout the oyster. Multicellular stages containing “merozoites or trophozoites,” may also be intrahaemocytic. Early infections occur in the digestive tract, gills, palps, and mantle. Advanced infections are associated with diffuse systemic parasitism, pronounced haemocytosis, and tissue lysis.

A zoospore stage has been found after hypnospores produced in RFTM are placed in seawater, as well as during *in vitro* propagation. This stage has not been recognized in oyster tissues. All stages found in the oyster appear to be infective, as is the zoospore; however, the significance of the zoospore in the life cycle is currently unknown.

Gross clinical signs

Dermo disease cannot be diagnosed based on gross clinical signs.

Control measures and legislation

Oysters from an enzootic area should never be introduced to an area where the pathogen is absent. Maintaining oysters at reduced salinities (<15) should inhibit infection development and mortality. If final conditioning at higher salinity is needed for market, it should be done as late in the season as possible to avoid the acquisition and development of new infections. It generally takes two years after initial exposure before serious mortalities begin; therefore, uninfected hatchery-produced seed deployed in late summer can usually avoid serious infection through the following summer and can be harvested that fall with little or no mortality. Selective breeding has produced strains with some improvement in survival. Particle filtration (1- μ m filters) and UV irradiation of water coming into or exiting hatcheries or nurseries can eliminate infective stages. Dermo disease is an OIE-notifiable disease.

Diagnostic methods

The standard assay involves incubation of tissues (typically rectum and a piece of mantle or gill) in Ray's Fluid Thioglycollate Medium (RFTM) for 5–7 days at 20–25°C (which allows the parasites to enlarge, but not to proliferate), then mincing the tissues on a slide and adding Lugol's Iodine. The enlarged cells, called "hypnospores" (which may be 100 to 300 microns in diameter) stain light-blue to blue-black and are observed microscopically. A total body burden assay, in which individual tissues or the entire oyster are incubated in RFTM then washed with NaOH to dissolve the host tissue, is more sensitive and accurate, but also more expensive and time consuming. Comparison of the two methods shows that the standard method does not consistently detect infections until the parasite density is $\geq 10^3$ to 10^4 gram⁻¹ wet weight of oyster tissue. Tissue section histology and RFTM incubation of hemolymph samples are less sensitive diagnostic techniques than standard RFTM incubation. The RFTM culture method detects all known species of *Perkinsus*; therefore it should not be used for diagnosis outside known ranges or hosts, or where more than one species is known to be prevalent. Both endpoint and quantitative PCR (polymerase chain reaction) assays are available for *P. marinus*; however, comparative assays have not always found them to be more sensitive than the RFTM assay.

References

- Andrews, J. D., and Ray, S. M. 1988. Management strategies to control the disease caused by *Perkinsus marinus*. In *Disease Processes in Marine Bivalve Molluscs*. Ed. by W. S. Fisher., American Fisheries Society, Bethesda, MD, USA, pp. 257–264.
- Burreson, E. M., Alvarez, R. S., Martinez, V. V., and Macedo, L. A. 1994. *Perkinsus marinus* (Apicomplexa) as a potential source of oyster *Crassostrea virginica* mortality in coastal lagoons of Tabasco, Mexico. *Diseases of Aquatic Organisms*, 20: 77–82.
- Bushek, D., Ford, S. E., and Allen, S. K. 1994. Evaluation of methods using Ray's fluid thioglycollate medium for diagnosis of *Perkinsus marinus* infection in the eastern oyster, *Crassostrea virginica*. *Annual Review of Fish Diseases*, 4: 201–217.
- Caceres-Martinez, J., Vasquez-Yeomans, R., Padilla-Lardizabal, G., and Portilla, M. A. R. 2008. *Perkinsus marinus* in pleasure oyster *Crassostrea corteziensis* from Nayarit, Pacific coast of Mexico. *Journal of Invertebrate Pathology*, 99: 66–73.
- De Faveri, J., Smolowitz, R., and Roberts, R. B. 2009. Development and validation of a real-time quantitative PCR assay for the detection and quantification of *Perkinsus marinus* in the Eastern oyster, *Crassostrea virginica*. *Journal of Shellfish Research*, 28: 459–464.
- Ford, S. E., and Tripp, M. R. 1996. Diseases and defense mechanisms. In *The Eastern Oyster Crassostrea virginica*. Ed. by R. I. E. Newell, V. S. Kennedy, and A. F. Eble. Maryland Sea Grant College, College Park, MD, USA, pp. 383–450.
- Ford, S. E., Xu, Z., and DeBrosse, G. 2001. Use of particle filtration and UV irradiation to prevent infection by *Haplosporidium nelsoni* (MSX) and *Perkinsus marinus* (Dermo) in hatchery-reared larval and juvenile oysters. *Aquaculture*, 194: 37–49.

- Gauthier, J. D., Miller, C. R., and Wilbur, A. E. 2006. TaqMan® MGB real-time PCR approach to quantification of *Perkinsus marinus* and *Perkinsus* spp. in oysters. *Journal of Shellfish Research*, 25: 619–624.
- Kern, F. G., Sullivan, L. C., and Takata, M. 1973. *Labyrinthomyxa*-like organisms associated with mass mortalities of oysters, *Crassostrea virginica*, from Hawaii. *Proceedings of the National Shellfisheries Association*, 63: 43–46.
- La Peyre, J. F., Faisal, M., and Burreson, E. M., 1993. In vitro propagation of the protozoan *Perkinsus marinus*, a pathogen of the eastern oyster, *Crassostrea virginica*. *Journal of Eukaryotic Microbiology*, 40: 304–310.
- Leander, B. S., and Keeling, P. J. 2004. Early evolutionary history of dinoflagellates and apicomplexans (Alveolata) as inferred from hsp90 and actin phylogenies. *Journal of Phycology*, 40: 341–350.
- Littlewood, D. T. J. 2000. First report of the protozoan *Perkinsus* cf. *marinus* in the mangrove oyster *Crassostrea rhizophorae* (Guilding). *Caribbean Journal of Science*, 36: 153–154.
- Mackin, J. G., Owen, H. M., and Collier, A. 1950. Preliminary note on the occurrence of a new protistan parasite, *Dermocystidium marinum* n. sp. in *Crassostrea virginica* (Gmelin). *Science*, 111: 328–329.
- Ragone Calvo, L. M., Calvo, G. W., and Burreson, E. M. 2003. Dual disease resistance in a selectively bred eastern oyster, *Crassostrea virginica*, strain tested in Chesapeake Bay. *Aquaculture*, 220: 69–87.
- Ray, S. M. 1966. A review of the culture method for detecting *Dermocystidium marinum*, with suggested modifications and precautions. *Proceedings of the National Shellfisheries Association*, 54: 55–69.
- Reece, K. S., Siddall, M. E., Burreson, E. M., and Graves, J. E. 1997. Phylogenetic analysis of *Perkinsus* based on actin gene sequences. *Journal of Parasitology*, 83: 417–423.
- Russell, S., Frasca, S., Sunila, I., and French, R. A. 2004. Application of a multiplex PCR for the detection of protozoan pathogens of the eastern oyster *Crassostrea virginica* in field samples. *Diseases of Aquatic Organisms*, 59: 85–91.
- Villalba, A., Reece, K. S., Ordas, M. C., Casas, S. M., and Figueras, A. 2004. Perkinsosis in molluscs: A review. *Aquatic Living Resources*, 17: 411–432.

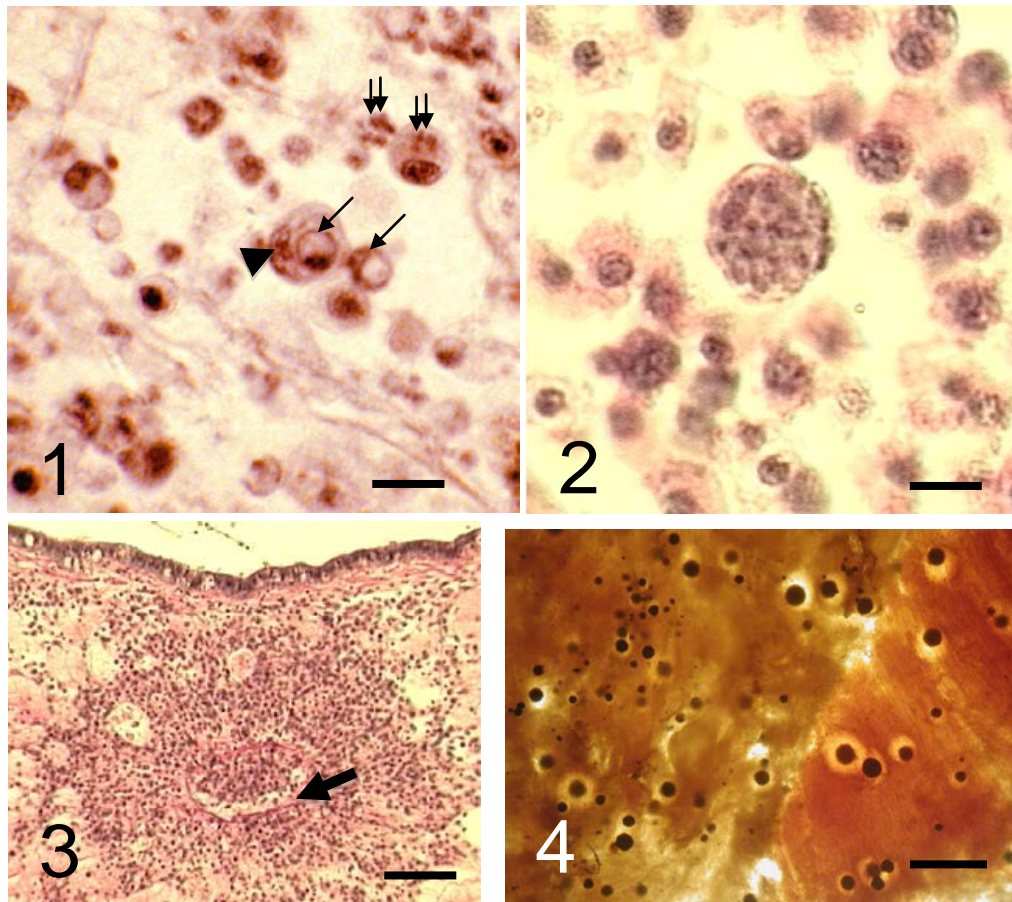


Figure 1. Tissue section showing *Perkinsus marinus* trophont (single-cell "signet ring" stage - long arrows) and early stage meronts with merozoites (double arrows). Phagocytic cells (arrowhead) have ingested some parasites. Scale bar = 5 μ m.

Figure 2. Tissue section showing large, late-stage *P. marinus* meront containing many merozoites. Scale bar = 5 μ m.

Figure 3. Tissue section showing condition known as "cuffing" of haemocytes around blood vessel (arrow) in mantle, which is typical of *P. marinus*-caused histopathology. Scale bar = 50 μ m.

Figure 4. Enlarged *P. marinus* hypnospores scattered throughout tissue that has been incubated in Ray's fluid thioglycollate medium (RFTM). Note "halo" of lysed tissue often observed around hypnospores. Scale bar = 100 μ m.

Author Contact Information

Susan E. Ford
 Rutgers University
 Haskin Shellfish Research Laboratory
 Port Norris, New Jersey, 08349 USA
susan@hsrl.rutgers.edu